



# Perioperative management of acetabular and pelvic fractures: evidence-based recommendations

Ramakanth R. Yakkanti<sup>1</sup> · Neil V. Mohile<sup>1</sup> · Wayne B. Cohen-Levy<sup>2</sup> · Sagie Haziza<sup>1</sup> · Matthew J. Lavelle<sup>1</sup> · Krishna G. Bellam<sup>3</sup> · Stephen M. Quinnan<sup>4</sup>

Received: 19 October 2021 / Accepted: 24 November 2021 / Published online: 2 December 2021  
© The Author(s), under exclusive licence to Springer-Verlag GmbH Germany, part of Springer Nature 2021

## Abstract

**Purpose** The American Academy of Orthopaedic Surgeons does not currently provide clinical practice guidelines for management of PAF. Accordingly, this article aims to review and consolidate the relevant historical and recent literature in important topics pertaining to perioperative management of PAF.

**Methods** A thorough literature review using PubMed, Cochrane and Embase databases was performed to assess preoperative, intraoperative and postoperative management of PAF fracture. Topics reviewed included: time from injury to definitive fixation, the role of inferior vena cava filters (IVCF), tranexamic acid (TXA) use, intraoperative cell salvage, incisional negative pressure wound therapy (NPWT), intraoperative antibiotic powder use, heterotopic ossification prophylaxis, and pre- and postoperative venous thromboembolism (VTE) prophylaxis.

**Results** A total of 126 articles pertaining to the preoperative, intraoperative and postoperative management of PAF were reviewed. Articles reviewed by topic include 13 articles pertaining to time to fixation, 23 on IVCF use, 14 on VTE prophylaxis, 20 on TXA use, 10 on cell salvage, 10 on iNPWT 14 on intraoperative antibiotic powder and 20 on HO prophylaxis. An additional eight articles were reviewed to describe background information. Five articles provided information for two or more treatment modalities and were therefore included in multiple categories when tabulating the number of articles reviewed per topic.

**Conclusion** The literature supports the use of radiation therapy for HO prophylaxis, early (<5 days from injury) surgical intervention and the routine use of intraoperative TXA. The literature does not support the routine use of iNPWT or IVCF. There is inadequate information to make a recommendation regarding the use of cell salvage and wound infiltration with antibiotic powder. While the routine use of chemical VTE prophylaxis is recommended, there is insufficient evidence to recommend the optimal agent and duration of therapy.

**Keywords** Pelvic fracture · Acetabular fracture · Concept review · Time to fixation · Tranexamic acid · Heterotopic ossification

## Introduction

Despite advancements in orthopedic surgical techniques, critical care medicine and multidisciplinary interventions, pelvic and acetabular fractures (PAF) remain complex injuries with relatively high morbidity and mortality [1–4]. One-year mortality ranges from 5 to 42%, with patient age, blood transfusions, Injury Severity Score, pelvic instability and open injury serving as important prognostic factors [5, 6]. The increased morbidity associated with these injuries can be attributed to hemorrhage, lengthy operative times, thromboembolic events and associated traumatic injuries [1–3, 5, 7].

✉ Sagie Haziza  
Sagiehaziza@gmail.com

<sup>1</sup> Department of Orthopaedic Surgery, University of Miami University Hospital, West Wing, 1321 NW 14th st, Suite 306, Miami, FL 33125, USA

<sup>2</sup> University Hospital/Case Western Reserve University, Cleveland, OH, USA

<sup>3</sup> Warren Alpert Medical School at Brown University, Providence, RI, USA

<sup>4</sup> The Paley Orthopedic and Spine Institute, West Palm Beach, FL, USA

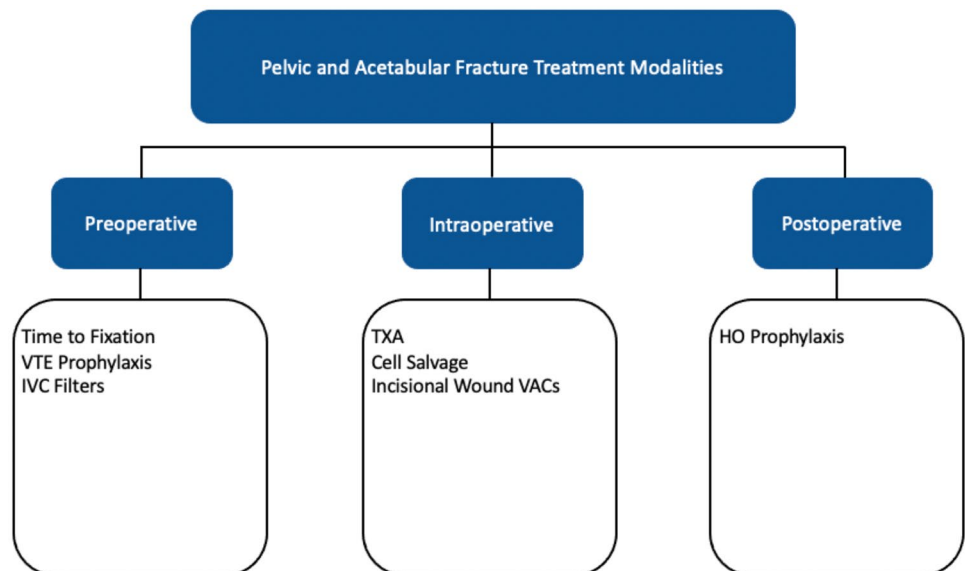
The American Academy of Orthopaedic Surgeons (AAOS) provides clinical practice guidelines on hip fracture management [8], but similar guidelines do not exist for PAF, likely owing to the relative infrequency with which these fractures are encountered. Treatment considerations in managing patients with these complex injuries include time from injury to definitive fixation, the role of inferior vena cava filters (IVCF), tranexamic acid (TXA) use, intraoperative cell salvage, incisional negative pressure wound therapy (NPWT), intraoperative antibiotic powder use, heterotopic ossification prophylaxis, and pre- and postoperative venous thromboembolism (VTE) prophylaxis.

The lack of consensus on management guidelines leaves many surgeons with questions as to the optimal treatment strategies to mitigate patient morbidity. Accordingly, this article aims to review and consolidate the relevant historical and recent literature in important topics pertaining to perioperative management of pelvic and acetabular fractures.

## Methods

To help organize the review, the topics of perioperative management were divided into three sections: preoperative considerations, intraoperative considerations and postoperative considerations (Fig. 1). A thorough literature review using PubMed, Cochrane and Embase databases was performed for each individual topic discussed. Topics reviewed included: time from injury to definitive fixation, the role of inferior vena cava filters (IVCF), tranexamic acid (TXA) use, intraoperative cell salvage, incisional negative pressure wound therapy (NPWT), intraoperative antibiotic powder use, heterotopic ossification prophylaxis, and pre- and postoperative venous thromboembolism (VTE) prophylaxis.

**Fig. 1** Pelvic and acetabular fracture treatment modalities (Microsoft PowerPoint)



Throughout the article the literature regarding each topic is summarized and a recommendation is given after critical appraisal of the relevant literature.

## Results

A total of 126 articles pertaining to the preoperative, intraoperative and postoperative management of PAF were reviewed. Articles reviewed by topic include 13 articles pertaining to time to fixation, 23 on IVCF use, 14 on VTE prophylaxis, 20 on TXA use, 10 on cell salvage, 10 on iNPWT 14 on intraoperative antibiotic powder and 20 on HO prophylaxis. An additional eight articles were reviewed to describe background information. Five articles provided information for two or more treatment modalities and were therefore included in multiple categories when tabulating the number of articles reviewed per topic.

## Discussion

### Preoperative considerations

#### Time to fixation

Thirteen articles were reviewed pertaining to time to fixation. Conflicting literature exists as to the optimal timing of surgical fixation of PAF. Central to the ambiguity is the fact that there is not established definition for “early” fixation in the literature, as the range has varied from < 24 h to 15 days from injury [9, 10]. More recent literature favors earlier surgical treatment [11–13] (Table 1.)

**Table 1** Time to fixation major findings/conclusion of relevant articles included in review

Author	Journal	Year of publication	Definition of early	Major finding/conclusion
<b>Morbidity and mortality</b>				
Vallier	Trauma, Injury, Infection and Critical Care	2010	<24 h	Early fixation of unstable PAF reduces morbidity (pulmonary, ARDS, MOF and ICU LOS)
Devaney	Trauma and Acute Care Surgery	2020	Continuous	Time to fixation for PAF has decreased over the last decade, especially in polytrauma and hemodynamically unstable patients. No change in mortality, LOS or ICU LOS
Harrison	Archives of Orthopaedic and Trauma Surgery	2021	<72 h	Geriatric (65+) patients with PAF early vs late fixation have similar 1 year mortality rates
Glogovac	Orthopaedic Trauma	2020	<48 h	Geriatric (65+) patients with acetabular fractures early vs late fixation have similar 30-day, 6-month, 1-year mortality rates, LOS, DVT
Emminghorst	Trauma, Injury, Infection and Critical Care	2010	<24 h	Pelvic ring fractures in polytrauma patients fixed early have no significantly increased rate of transfusion, LOS, ICU LOS or mortality
Ding	Orthopaedic Trauma	2018	Continuous	Delays in acetabular fracture fixation leads to increased reoperations for infection
<b>Quality of reduction</b>				
Madhu	Bone and Joint Surgery	2006	Continuous and categorical (anatomic reduction and functional outcomes, respectively): Elementary—<15 days and <15 days Associated—<5 days and <10 days	Early fixation of elementary and associated fractures leads to better anatomic reduction and functional outcomes
Mears	Clinical Orthopaedics and Related Research	2003	<11 days	Anatomic reductions in displaced acetabular fractures lead to better clinical outcomes (HHS). Delays of >11 days lead to poor radiographic and clinical outcomes
Dailey	Orthopaedic Trauma	2016	Continuous	Earlier operative intervention in acetabular fractures improves probability of achieving anatomic reduction
<b>Second hit immune response</b>				
Katsoulis	Injury	2006	4 days	In polytrauma, damage control orthopedics should be performed, and definitive fixation should be completed after 4 days
Pape	Trauma, Injury, Infection and Critical Care	2001	Early: 2–4 days Late: 5–8 days	Secondary surgery in early vs late blunt trauma patients is associated with increased postoperative organ dysfunction
Pape	Trauma, Injury, Infection and Critical Care	2008	<24 h	Perioperative cytokines (IL-6,8) concentration is associated with increased blood loss in PAF surgery
Qiao	European Journal of Trauma and Emergency Surgery	2018	<24 h	IL-6 levels within 1 day of trauma surgery can be used to help predict mortality, multiple organ failure and dysfunction

LOS length of stay, ICU intensive care unit, ARDS acute respiratory distress syndrome, MOF multiple organ failure, DVT deep vein thrombosis, HHS Harris Hip Score, IL interleukin, PAF pelvic and acetabular fracture

Studies demonstrate early fixation can reduce morbidity in unstable PAF patients. Two retrospective studies showed early fixation in PAF fractures, < 24 h vs > 24 h and 5.5 h vs 5 days, resulted in fewer complications including shorter ICU days, ARDS, pneumonia, DVT and overall pulmonary complications [9, 14]. Enninghorst et al. further concluded that ORIF of unstable pelvic ring fractures is safe within 6 h. Ding et al. reviewed 791 acetabular fractures and found that increased time to fixation was associated with increased risk of infection with incidence as high as 40% with > 10 days of delay, compared to 15% for > 2 days of delay [15]. However, evidence suggests that there is no significant difference in 30-day, 60-day and 1-year mortality rates between geriatric PAF patients operated on within < 72 h compared to those operated on > 72 h [12, 13]

Furthermore, delays in surgical fixation have been shown to significantly reduce the quality of fracture reduction [16, 17]. Using logistic regression analysis, Dailey et al. showed that each day without operative intervention decreased the odds of anatomic reduction by 12% [17]. When assessing time to surgery as a categorical value, however, Madhu et al. showed that anatomical reduction was only negatively affected when time to surgery was greater than 15 days and greater than 5 days for elementary pattern and associated pattern fractures, respectively [10]. In their retrospective cohort of 650 acetabular fracture patients, Dailey et al. found that patients reduced within 3 days vs 4.5 days vs 7 days had good (displacement  $\leq$  1 mm), imperfect (2–3 mm) and poor (> 3 mm) anatomic reductions, respectively [17]. Good anatomic reduction, coupled with findings of equivalent mortality and lower infection incidence has led several to conclude that early reduction is advised in PAF surgery [12, 15, 17].

Historically, definitive fixation was delayed due to the immense pro-inflammatory surge that occurs in polytrauma patients with these fracture patterns [3]. Seminal work by Pape and colleagues demonstrated a second surge, termed “second hit” by the authors, of IL-6 in patients treated early which raised concerns for potential multisystem organ failure [18, 19]. Injury Severity Score (ISS) and IL-6 inflammatory marker are metrics used in predicting multisystem organ failure. In their study, Pape et al. found significantly more organ dysfunction in orthopedic fracture patients definitively fixed 2–4 days after injury versus those fixed 5–8 days after injury [18, 20].

**Recommendation** Evidence suggests that fixation in the first 3–5 days increases the probability of achieving anatomic alignment, reduces complication rates, and improves clinical outcomes without increasing mortality. While earlier studies had raised concerns for a “second hit”, more recent evidence suggests that early fixation is safe.

## IVC filters

Twenty-three articles were reviewed pertaining to IVC filter use as a preoperative management modality. PAFs are associated with disruption of pelvic vascular structures (at the time of trauma or operative fixation) and require prolonged immobilization often leading to increased venous thromboembolism (VTE) risk [21, 22]. Deep vein thrombosis (DVT) incidence ranges from 35 to 61% [23–25]. Patients with contraindications to chemical prophylaxis often have IVCF placed to prevent resultant complications of pulmonary embolisms (PE) [21, 26, 27]. They may be placed therapeutically in those with diagnosed DVTs, or prophylactically in those at risk for developing a PE.

Historical studies investigating the use of prophylactic IVCF in high-risk trauma patients concluded that the intervention significantly reduces PEs [21, 28, 29]. A systematic review from 2012 highlighted that few high-quality prospective randomized studies existed at the time [30]. One early randomized clinical trial (RCT) found IVCF efficacious in reducing PE, but could not find a statistical reduction in mortality rate [31].

IVCF are not benign and can result in complications such as recurrent DVTs, vascular injury, filter migration, lower extremity edema, IVC thrombosis and in extreme cases phlegmasia cerulea dolens [26, 31–33]. Retrievable filters were introduced to mitigate these complications, though their retrieval was often less than 60% [34, 35]. Cherry et al. showed that retrievable filters did not demonstrate a significant reduction in PE and that patients had 9% incidence of recurrent DVT [35]. Conversely, Toro et al. demonstrated effective prevention of PE and negligible complications with filter use in PAF patients diagnosed with preoperative DVT compared to other high-risk trauma groups, though other studies specific to these patients present less convincing evidence for their efficacy [36, 37]. Recent studies by Cohen-Levy et al. and Stein et al. exhibited no significant reduction in PE rates with IVCF placement in PAF patients [38, 39].

ACCP guidelines do not currently recommend the use of IVC filters as thromboprophylaxis for high-risk patients unless there exist both a proven proximal DVT and also absolute contradiction to full dose anticoagulation or urgent surgery [40, 41]. No strong recommendations can be made regarding IVC filter use in patients without any evidence of existing DVT [40, 41].

**Recommendation** The use of IVC filters is not supported by recent, high-quality evidence. Furthermore, there are potential long-term sequelae from use of permanent or retrievable IVC filters as well as evidence that retrievable filters are not often retrieved. Consideration of IVCF should be reserved for a limited subset cases where chemical and mechanical VTE prophylaxis cannot otherwise be used [42, 43].

## Chemical venous thromboembolism (VTE) prophylaxis

Fourteen articles were reviewed pertaining to VTE prophylaxis as a perioperative management modality. Despite the increased risk of VTE in PAF patients, no established guidelines exist regarding prophylaxis [43–47]. Recent investigations in patients with PAF found that routine duplex ultrasonographic screening should not be performed as has not been shown to reduce the incidence of pulmonary embolism (PE) [48]. However, it is important to consider other concomitant injuries as well as delays in initiation of chemical prophylaxis as routine screening may have a role in higher-risk patients [27, 49]

Generally, major orthopedic surgery utilizes many different antithrombotic prophylaxis treatments [40]. In PAF studies, LMWH has been the most studied. Steele et al. showed LMWH is both safe and effective in VTE reduction especially when administered within 24 h of injury [7]. Administration methods include once daily fixed dose or single dose adjusted to body weight [50]. Recent studies assessing direct oral anticoagulants (DOAC) in pelvic trauma patients have demonstrated their safety and superiority to LMWH in reducing DVT, but not PE or in-hospital mortality incidence [25, 51]. Lastly, there is some evidence to support preoperative suspension of anticoagulation prior to internal fixation in order to reduce blood loss and operative time [52].

**Recommendation** There is insufficient evidence to offer a recommendation on the type or duration of chemical VTE prophylaxis. The authors' practice is to discontinue chemical prophylaxis the night prior to surgery and resume on postoperative day 1.

## Intraoperative considerations

### TXA use

Twenty articles were reviewed pertaining to TXA use as a perioperative management modality. Transfusion is required in 24% of isolated pelvic fractures, 35% of isolated acetabular fractures and 57% of combination injuries [53]. Allogenic transfusions are associated with transmission of infectious disease, transfusion reaction, acute lung injury, DVT, and postoperative infection [54, 55]. Accordingly, strategies to mitigate blood loss are critical to mitigating morbidity [56–58].

Tranexamic acid (TXA) is an antifibrinolytic agent whose use has increased in the US due to its efficacy in reducing blood loss and safety [57, 59, 60]. The 2013 CRASH-2 RCT demonstrated TXA a cost-effective treatment in reducing mortality when administered less than 3 h from injury among trauma patients [61]. Much of the literature on TXA in orthopedic surgery comes from the total joint replacement

and spine literature [62–64] and more recently traumatology and hip fracture surgery [65–68]. Therefore, clinical trials on TXA use in PAF surgery have been recommended [69].

Two RCTs exploring the effects of intravenous TXA in PAF patients found that TXA offered no significant reduction in transfusion incidence, though one noted a reduction of total blood loss [70, 71]. Both also concluded no significant increase in VTE with TXA use [70, 71].

Conversely, one recent retrospective study demonstrated significantly decreased mean intraoperative blood loss, postoperative drain collection and postoperative transfusion rates with TXA use in PAF surgery [72]. Similarly, Cohen-Levy et al. determined that intraoperative TXA along with suspension of DVT chemoprophylaxis prior to surgery produced a 20.7% reduction in blood product transfusion, 36-min reduction in operative time and did not result in higher rates of VTE in these patients [52].

Though there is no consistent dosage of TXA agreed upon in literature, most centers administer a preoperative dose, followed by a dose several hours after surgery or a dose near closure. Doses range from 10 to 15 mg/kg or 1–3 g [52, 70–72].

**Recommendation** High-quality evidence favoring the use of TXA in PAF is lacking, although lower-quality studies do support their use. As no study has demonstrated an increased rate of DVT or PE associated with their use, the authors would recommend in favor of their routine use.

### Cell salvage

Ten articles were reviewed pertaining to cell salvage as an intraoperative management modality. Intraoperative cell salvage devices have increasingly been adopted in the setting of major orthopedic trauma [73–75]. These devices salvage red blood cells from the operative field, extensively wash them of contaminants, resuspend them in a saline solution and then transfuse them into the patient [75, 76]. While literature on the matter is controversial, relative contraindications to cell salvage include concurrent use of pharmacologic agents (clotting factors, irrigating solutions), obvious contaminants (bowel or bladder injury), malignancy and pre-existing hematologic disorders [77].

Cell salvage has been investigated in revision hip arthroplasty, lumbar spine surgery and trauma surgery [74, 76, 78–80]. A meta-analysis of RCTs demonstrated decreased patient exposure to allogeneic blood transfusions when cell salvage was used in orthopedic surgery [81]. However, in the setting of PAF, recent literature demonstrates conflicting reports to its efficacy. Three recent retrospective studies found no reduction in allogeneic blood transfusions [73, 75, 82]. In fact, Scannell et al. found that blood-related expenses significantly increased with the use of cell salvage [75]. On

the contrary, Bigsby et al. and Odak et al. found the use of cell salvage is clinically efficacious and cost-effective in PAF; however, these studies lacked a control group for direct comparison [74, 78].

**Recommendation** Based on the current literature, there is insufficient evidence to recommend for or against the use of cell salvage.

#### Incisional negative pressure wound therapy (iNPWT)

Ten articles were reviewed pertaining to iNPWT. Acetabular fractures are often the result of high-energy trauma leading to additional open soft tissue and bony injuries, leading to infection rates ranging from 5 to 12% [83–86]. Negative pressure wound therapy (NPWT) has traditionally been used in the setting of acute and chronic soft tissue wounds; however, recent literature demonstrates an increasing role in closed incisions (iNPWT) following high-risk orthopedic injuries, including PAF [83, 87].

NPWT accelerates wound healing via (1) mechanical properties: promoting blood flow to the wound, maintaining a moist environment, reducing edema, placing the wound under tension and (2) biochemical properties: leading to alterations in the microbial milieu [87–90]. While previous studies advocated for its use, in a recent Wound Healing in Surgery for Trauma (WHIST) RCT, which included 1548 patients, Costa et al. found no statistical difference with the use of iNPWT for surgical wounds associated with lower limb fractures from major trauma [83, 90–92]. While this RCT was specific to lower extremity fractures, it remains of value as previous studies comparing iNPWT to standard surgical dressings in the context of PAF were retrospective and considerably smaller [83, 90]. Additionally, Crist et al. performed a recent RCT specific to patients with acetabular fractures and found comparable results with no decrease in the incidence of deep infections with the use of iNPWT [87].

**Recommendation** NPWT is more costly than conventional surgical dressings and recent investigations have failed to demonstrate clinical benefit for preventing surgical site infections.

#### Antibiotic powder

Fourteen articles were reviewed on the use of antibiotic powder intraoperatively. While IV perioperative antibiotics are the gold standard for preventing SSIs, local delivery of antibiotics has been of increased interest due to its limited systemic toxicity and ability to achieve high concentrations at the surgical site. Surgical wounds often consist of local areas of hematoma, seroma and tissue ischemia, which are inaccessible to systemically administered antibiotics [93,

94]. This is often amplified in trauma due to the presence of significant soft tissue disruption. In the setting of spine surgery, many studies have demonstrated that topical administration of vancomycin powder to the surgical site in addition to standard IV antibiotic prophylaxis reduces the incidence of SSI from 3 to 15 to 0.2% or lower [95–99]. The intervention has also recently been demonstrated effective in total joint arthroplasty [100, 101]. One meta-analysis showed at least 65% less superficial and deep SSI in both total hip and knee replacement surgeries with local vancomycin administration [101]. Other studies have determined vancomycin powder efficacious in reducing bacterial load and preventing deep surgical site infections in high-risk orthopedic trauma patients [99, 102]. As a result of convincing evidence, O'Toole et al. conducted a randomized clinical trial across 34 US trauma centers on local administration of vancomycin powder in definitive fixation of tibial plateau and pilon fracture surgery [103, 104]. The addition of 1000 mg sterile vancomycin powder led to a 35% relative risk reduction of deep surgical wounds within 6 months compared to controls [104].

Less data have been reported on PAF surgery, though few retrospective studies have been published. Owen et al. investigated the efficacy of topical vancomycin and tobramycin powder in reducing the incidence of SSI after PAF surgery [105]. They found a significant decrease in the incidence of infection for patients with low levels of intraoperative blood loss [105]. However, the protective effects were not demonstrated in patients with greater than 1 l of intraoperative blood loss [105]. More recently, however, Cichos et al. demonstrated no superiority of vancomycin and tobramycin powder in reducing either deep or superficial SSI compared to standard saline irrigation in acetabular patients who underwent ORIF [106].

**Recommendation** Insufficient evidence exists to recommend for or against the routine use of antibiotic powder in PAF exclusively; however, their use is supported in other clinical situations within orthopedic trauma and other subspecialties without significant complications. Thus, it is the view of the authors that routine use of antibiotic powder should be part of the arsenal available to surgeons as part of the infection prevention protocol.

#### Postoperative considerations

##### HO prophylaxis

Twenty articles were reviewed pertaining to HO prophylaxis. Heterotopic ossification (HO) is the formation of mature lamellar bone in non-osseous tissues [107, 108]. It occurs in up to 58% of patients who undergo internal fixation of PAF, is diagnosed radiographically and commonly manifests

**Table 2** Summary of recommendations

	Intervention	Recommendation
Preoperative	Early surgical intervention	For
	IVCF	Against
	Chemical VTE prophylaxis	Indeterminate
Intraoperative	TXA	For
	Cell salvage	Indeterminate
	INPWT	Against
	Antibiotic powder	Indeterminate
Postoperative	NSAID for HO prophylaxis	Indeterminate
	Radiation therapy for HO prophylaxis	For

as symptomatic stiffness of the joint with decreased range of movement [109–112]. The trigger for HO following major hip procedures is unknown, but several risk factors have been named, including delay in internal fixation, prolonged mechanical ventilation, diffuse idiopathic skeletal hyperostosis, Paget's disease and the use of the Kocher Langenback surgical approach [110–112]. The severity is determined using the Brooker classification grading (0 to IV), which takes into account the size of bone islands in the soft tissue and their relative position to the acetabulum and pelvis [113].

The only treatment option for established HO is delayed surgical resection when the heterotopic bone has matured and encapsulated, approximately 6 months postoperatively, though complication of extreme blood loss, poor abductor function and abnormal gait can occur [108, 114]. Prophylactic measures include NSAIDs or radiation [115]. However, both have side effects such as gastric ulcers, renal toxicity, fracture nonunion (NSAIDs) and malignancy (irradiation) [116]. Most commonly, NSAID prophylaxis is given as indomethacin in a 25-mg dose, three times a day, for 7–14 days postoperatively [116].

Several studies have suggested that the use of indomethacin as a prophylactic agent is effective in reducing the incidence of clinically significant HO after acetabular surgery [117, 118]. When comparing placebo to 3 days, 1 week and 6 weeks of indomethacin treatment, one RCT found reduced HO with 1 week of treatment though 6 weeks of prophylaxis increased incidence of fracture nonunion [118]. However, others have demonstrated contradictory evidence [116, 119, 120]. Interestingly, Cheng et al. demonstrated reduced HO formation with use of combination treatment of parecoxib and celecoxib [121].

Radiation therapy (RT) is another commonly used prophylactic modality [122]. Several studies have revealed its efficacy in reducing both total and severe HO incidence [123–125]. Childs et al. showed RT reduced HO formation by nearly 55% [107]. Moreover, RT has proven as effective

as indomethacin [117] and safer [108]. Potential complications include carcinogenesis and infertility, though the risk is considered minimal, and documentation of adverse events are scarce [126].

RT therapy has been demonstrated effective in preventing HO in PAF patients up to 3 days postoperatively [107], with data showing a significant increase from 10% HO incidence within 3 days of injury to 92% with treatment greater than 21 days after initial injury [122]. Thus, RT should be administered as early as clinically possible after the trauma.

**Recommendation** Both indomethacin and single-dose radiation therapy can be effective for the prevention of HO after surgery for PAF; however, there is conflicting literature with regard to indomethacin's efficacy and potential nonunion incidence. RT has proven to be a more predictable surgical adjunct to prevent HO in PAF patients.

## Conclusions

Many questions remain regarding the management of patients with PAF. As demonstrated above, there is a lack of available high-quality literature in regard to perioperative management. Based on the current review, our recommendations are as follows: the literature supports the use of radiation therapy for HO prophylaxis, early (<5 days from injury) surgical intervention and the routine use of intraoperative TXA. The literature does not support the routine use of iNPWT or IVCF. There is inadequate information to make a recommendation regarding the use of cell salvage and wound infiltration with antibiotic powder. While the routine use of chemical VTE prophylaxis is recommended, there is insufficient evidence to recommend the optimal agent and duration of therapy (Table 2).

**Author contributions** This article had equal contribution from all authors. The idea for the article came from RY, WC-L and SQ. All authors including those mentioned and NM, SH, ML and KB contributed to literature review, manuscript preparation and revision.

**Funding** No funding was received for conducting this study.

**Data availability** Not applicable.

**Code availability** Not applicable.

## Declarations

**Conflict of interest** The authors have no relevant financial or non-financial interests to disclose.

**Ethics approval** Ethics approval was waived.

**Consent to participate** Not applicable.

**Consent for publication** Not applicable.

## References

- Hill BW, Switzer JA, Cole PA (2012) Management of high-energy acetabular fractures in the elderly individuals: a current review. *Geriatr Orthop Surg Rehabil* 3:95–106. <https://doi.org/10.1177/2151458512454661>
- Halawi MJ (2016) Pelvic ring injuries: surgical management and long-term outcomes. *J Clin Orthop Trauma* 7:1–6
- Katsoulis E, Giannoudis PV (2006) Impact of timing of pelvic fixation on functional outcome. *Injury* 37:1133–1142. <https://doi.org/10.1016/j.injury.2006.07.017>
- Bundgaard H, Møss J (1989) Prodrugs of peptides IV: bioreversible derivatization of the pyroglutamyl group by *N*-acylation and *N*-aminomethylation to effect protection against pyroglutamyl aminopeptidase. *J Pharm Sci* 78:122–126. <https://doi.org/10.1002/jps.2600780210>
- Smith W, Williams A, Agudelo J et al (2007) Early predictors of mortality in hemodynamically unstable pelvis fractures. *J Orthop Trauma* 21:31–37. <https://doi.org/10.1097/BOT.0b013e31802ea951>
- Chong KH, DeCoster T, Osler T, Robinson B (1997) Pelvic fractures and mortality. *Iowa Orthop J* 17:110–114
- Steele N, Dodenhoff RM, Ward AJ, Morse MH (2005) Thromboprophylaxis in pelvic and acetabular trauma surgery. *J Bone Jt Surg Ser B* 87:209–212. <https://doi.org/10.1302/0301-620X.87B2.14447>
- Roberts KC, Brox WT (2015) AAOS clinical practice guideline: management of hip fractures in the elderly. *J Am Acad Orthop Surg* 23:138–140. <https://doi.org/10.5435/JAAOS-D-14-00433>
- Vallier HA, Cureton BA, Ekstein C et al (2010) Early definitive stabilization of unstable pelvis and acetabulum fractures reduces morbidity. *J Trauma Inj Infect Crit Care* 69:677–684. <https://doi.org/10.1097/TA.0b013e3181e50914>
- Madhu R, Kotnis R, Al-Mousawi A et al (2006) Outcome of surgery for reconstruction of fractures of the acetabulum. *J Bone Jt Surg Ser B* 88:1197–1203
- Devaney GL, Bulman J, King KL, Balogh ZJ (2020) Time to definitive fixation of pelvic and acetabular fractures. *J Trauma Acute Care Surg* 89:730–735. <https://doi.org/10.1097/TA.00000000000002860>
- Harrison A, Ordas-Bayon A, Chimutengwende-Gordon M et al (2021) Factors associated with mortality in older patients sustaining pelvic or acetabular fractures. *Arch Orthop Trauma Surg.* <https://doi.org/10.1007/s00402-021-03873-5>
- Glogovac G, Le TT, Archdeacon MT (2020) Time to surgery and patient mortality in geriatric acetabular fractures. *J Orthop Trauma* 34:310–315. <https://doi.org/10.1097/BOT.0000000000001717>
- Enninghorst N, Toth L, King KL et al (2010) Acute definitive internal fixation of pelvic ring fractures in polytrauma patients: a feasible option. *J Trauma Inj Infect Crit Care* 68:935–939. <https://doi.org/10.1097/TA.0b013e3181d27b48>
- Ding A, O'Toole RV, Castillo R et al (2018) Risk factors for early reoperation after operative treatment of acetabular fractures. *J Orthop Trauma* 32:E251–E257
- Mears DC, Velyvis JH, Chang CP (2003) Displaced acetabular fractures managed operatively: indicators of outcome. *Clin Orthop Relat Res.* <https://doi.org/10.1097/00003086-200302000-00026>
- Dailey SK, Phillips CT, Radley JM, Archdeacon MT (2016) Achieving anatomic acetabular fracture reduction—when is the best time to operate? *J Orthop Trauma* 30:426–431. <https://doi.org/10.1097/BOT.0000000000000576>
- Pape HC, Van Griensven M, Rice J et al (2001) Major secondary surgery in blunt trauma patients and perioperative cytokine liberation: determination of the clinical relevance of biochemical markers. *J Trauma Inj Infect Crit Care* 50:989–1000
- Qiao Z, Wang W, Yin L et al (2018) Using IL-6 concentrations in the first 24 h following trauma to predict immunological complications and mortality in trauma patients: a meta-analysis. *Eur J Trauma Emerg Surg* 44:679–687
- Pape HC, Griensven MV, Hildebrand FF et al (2008) Systemic inflammatory response after extremity or truncal fracture operations. *J Trauma Inj Infect Crit Care* 65:1379–1384. <https://doi.org/10.1097/TA.0b013e31818c8e8c>
- Carlin AM, Tyburski JG, Wilson RF, Steffes C (2002) Prophylactic and therapeutic inferior vena cava filters to prevent pulmonary emboli in trauma patients. *Arch Surg* 137:521–527
- Kim JW, Oh CW, Oh JK et al (2014) The incidence and the risk factors of venous thromboembolism in Korean patients with pelvic or acetabular fractures. *J Orthop Sci* 19:471–477. <https://doi.org/10.1007/s00776-014-0553-z>
- Sharma OP, Oswanski MF, Joseph RJ et al (2007) Venous thromboembolism in trauma patients. *Am Surg* 73:1173–1180. <https://doi.org/10.1177/000313480707301121>
- Greenfield LJ, Proctor MC, Rodriguez JL et al (1997) Post-trauma thromboembolism prophylaxis. *J Trauma Inj Infect Crit Care* 42:100–103. <https://doi.org/10.1097/00005373-199701000-00017>
- Monzon DG, Iserson KV, Cid A, Vazquez JA (2012) Oral thromboprophylaxis in pelvic trauma: a standardized protocol. *J Emerg Med* 43:612–617. <https://doi.org/10.1016/j.jemermed.2011.09.006>
- Hoff WS, Hoey BA, Wainwright GA et al (2004) Early experience with retrievable inferior vena cava filters in high-risk trauma patients. *J Am Coll Surg* 199:869–874. <https://doi.org/10.1016/j.jamcollsurg.2004.07.030>
- Chana-Rodríguez F, Mañanes RP, Rojo-Manaute J et al (2015) Methods and guidelines for venous thromboembolism prevention in polytrauma patients with pelvic and acetabular fractures. *Open Orthop J* 9:313–320. <https://doi.org/10.2174/1874325001509010313>
- Gosin JS, Graham AM, Ciocca RG, Hammond JS (1997) Efficacy of prophylactic vena cava filters in high-risk trauma patients. *Ann Vasc Surg* 11:100–105
- Rogers FB, Shackford SR, Wilson J et al (1993) Prophylactic vena cava filter insertion in severely injured trauma patients: indications and preliminary results. *J Trauma Inj Infect Crit Care* 35:637–642. <https://doi.org/10.1097/00005373-199310000-00021>
- Kidane B, Madani AM, Vogt K et al (2012) The use of prophylactic inferior vena cava filters in trauma patients: a systematic review. *Injury* 43:542–547
- Decousus H, Leizorovicz A, Parent F et al (1998) A clinical trial of vena caval filters in the prevention of pulmonary embolism in patients with proximal deep-vein thrombosis. *N Engl J Med* 338:409–416. <https://doi.org/10.1056/nejm199802123380701>
- Stein PD, Matta F, Hull RD (2011) Increasing use of vena cava filters for prevention of pulmonary embolism. *Am J Med* 124:655–661. <https://doi.org/10.1016/j.amjmed.2011.02.021>
- Mesfin A, Lum YW, Nayfeh T, Mears SC (2011) Compartment syndrome in patients with massive venous thrombosis after inferior vena cava filter placement. *Orthopedics.* <https://doi.org/10.3928/01477447-20110124-23>

34. Pickham DM, Callcut RA, Maggio PM et al (2012) Payer status is associated with the use of prophylactic inferior vena cava filter in high-risk trauma patients. *Surg (United States)* 152:232–237. <https://doi.org/10.1016/j.surg.2012.05.041>
35. Cherry RA, Nichols PA, Snavelly TM et al (2008) Prophylactic inferior vena cava filters: do they make a difference in trauma patients? *J Trauma Inj Infect Crit Care* 65:544–548. <https://doi.org/10.1097/TA.0b013e31817f980f>
36. Toro JB, Gardner MJ, Hierholzer C et al (2008) Long-term consequences of pelvic trauma patients with thromboembolic disease treated with inferior vena caval filters. *J Trauma Inj Infect Crit Care* 65:25–29. <https://doi.org/10.1097/TA.0b013e318075e97a>
37. Webb LX, Rush PT, Fuller SB, Meredith JW (1992) Greenfield filter prophylaxis of pulmonary embolism in patients undergoing surgery for acetabular fracture. *J Orthop Trauma* 6:139–145. <https://doi.org/10.1097/00005131-199206000-00002>
38. Cohen-Levy WB, Liu J, Sen M et al (2019) Prophylactic inferior vena cava filters for operative pelvic fractures: a twelve year experience. *Int Orthop* 43:2831–2838. <https://doi.org/10.1007/s00264-019-04384-0>
39. Stein PD, Matta F, Hughes MJ (2018) Prophylactic inferior vena cava filters in patients with fractures of the pelvis or long bones. *J Clin Orthop Trauma* 9:175–180. <https://doi.org/10.1016/j.jcot.2017.09.018>
40. Falck-Ytter Y, Francis CW, Johanson NA et al (2012) Prevention of VTE in orthopedic surgery patients. Antithrombotic therapy and prevention of thrombosis, 9th ed: American College of Chest Physicians evidence-based clinical practice guidelines. *Chest* 141:e278S–e325S. <https://doi.org/10.1378/chest.11-2404>
41. Geerts WH, Bergqvist D, Pineo GF et al (2008) Prevention of venous thromboembolism: American College of Chest Physicians evidence-based clinical practice guidelines (8th edition). *Chest* 133:381S–453S. <https://doi.org/10.1378/chest.08-0656>
42. Collins DN, Barnes CL, McCowan TC et al (1992) Vena caval filter use in orthopaedic trauma patients with recognized pre-operative venous thromboembolic disease. *J Orthop Trauma* 6:135–138. <https://doi.org/10.1097/00005131-199206000-00001>
43. Lorch H, Welger D, Wagner V et al (2000) Current practice of temporary vena cava filter insertion: a multicenter registry. *J Vasc Interv Radiol* 11:83–88. [https://doi.org/10.1016/S1051-0443\(07\)61287-1](https://doi.org/10.1016/S1051-0443(07)61287-1)
44. Wang P, Kandemir U, Zhang B et al (2019) Incidence and risk factors of deep vein thrombosis in patients with pelvic and acetabular fractures. *Clin Appl Thromb.* <https://doi.org/10.1177/1076029619845066>
45. Arroyo W, Nelson KJ, Belmont PJ et al (2013) Pelvic trauma: what are the predictors of mortality and cardiac, venous thromboembolic and infectious complications following injury? *Injury* 44:1745–1749. <https://doi.org/10.1016/j.injury.2013.08.007>
46. Karunakar MA, Shah SN, Jerabek S (2005) Body mass index as a predictor of complications after operative treatment of acetabular fractures. *J Bone Jt Surg Ser A* 87:1498–1502
47. Sen RK, Kumar A, Tripathy SK et al (2011) Risk of postoperative venous thromboembolism in Indian patients sustaining pelvis-acetabular injury. *Int Orthop* 35:1057–1063. <https://doi.org/10.1007/s00264-010-1093-6>
48. Moed BR, Miller JR, Tabaie SA (2012) Sequential duplex ultrasound screening for proximal deep venous thrombosis in asymptomatic patients with acetabular and pelvic fractures treated operatively. *J Trauma Acute Care Surg* 72:443–447. <https://doi.org/10.1097/TA.0b013e318241090d>
49. Kay AB, Morris DS, Woller SC et al (2021) Trauma patients at risk for venous thromboembolism who undergo routine duplex ultrasound screening experience fewer pulmonary emboli: a prospective randomized trial. *J Trauma Acute Care Surg* 90:787–796
50. Haentjens P, Blaimont B et al (1996) Thromboembolic prophylaxis in orthopaedic trauma patients: a comparison between a fixed dose and an individually adjusted dose of a low molecular weight heparin (nadroparin calcium). *Injury* 27:385–390. [https://doi.org/10.1016/0020-1383\(96\)00042-3](https://doi.org/10.1016/0020-1383(96)00042-3)
51. Hamidi M, Zeeshan M, Sakran JV et al (2019) Direct oral anticoagulants vs low-molecular-weight heparin for thromboprophylaxis in nonoperative pelvic fractures. *J Am Coll Surg* 228:89–97. <https://doi.org/10.1016/j.jamcollsurg.2018.09.023>
52. Cohen-Levy WB, Rush AJ, Goldstein JP et al (2020) Tranexamic acid with a pre-operative suspension of anticoagulation decreases operative time and blood transfusion in the treatment of pelvic and acetabulum fractures. *Int Orthop* 44:1815–1822. <https://doi.org/10.1007/s00264-020-04595-w>
53. Magnussen RA, Tressler MA, Obremkey WT, Kregor PJ (2007) Predicting blood loss in isolated pelvic and acetabular high-energy trauma. *J Orthop Trauma* 21:603–607
54. Alter HJ, Harvey GK (2008) The hazards of blood transfusion in historical perspective. *Blood* 112:2617–2626. <https://doi.org/10.1182/blood-2008-07-077370>
55. Goel R, Patel EU, Cushing MM et al (2018) Association of perioperative red blood cell transfusions with venous thromboembolism in a North American Registry. *JAMA Surg* 153:826–833. <https://doi.org/10.1001/jamasurg.2018.1565>
56. Eubanks JD (2010) Antifibrinolytics in major orthopaedic surgery. *J Am Acad Orthop Surg* 18:132–138
57. Jennings JD, Solarz MK, Haydel C (2016) Application of tranexamic acid in trauma and orthopedic surgery. *Orthop Clin N Am* 47:137–143
58. Timmouth AT, McIntyre LA, Fowler RA (2008) Blood conservation strategies to reduce the need for red blood cell transfusion in critically ill patients. *CMAJ* 178:49–57
59. Lijnen HR (2001) Elements of the fibrinolytic system. *Ann N Y Acad Sci* 936:226–236
60. Amer KM, Rehman S, Amer K, Haydel C (2017) Efficacy and safety of tranexamic acid in orthopaedic fracture surgery: a meta-analysis and systematic literature review. *J Orthop Trauma* 31:520–525
61. Roberts I, Shakur H, Coats T et al (2013) The CRASH-2 trial: a randomised controlled trial and economic evaluation of the effects of tranexamic acid on death, vascular occlusive events and transfusion requirement in bleeding trauma patients. *Health Technol Assess (Rockv)* 17:1–80. <https://doi.org/10.3310/hta17100>
62. Xu S, Chen JY, Zheng Q et al (2019) The safest and most efficacious route of tranexamic acid administration in total joint arthroplasty: a systemic review and network meta-analysis. *Thromb Res* 176:61–66. <https://doi.org/10.1016/j.thromres.2019.02.006>
63. Winter SF, Santaguida C, Wong J, Fehlings MG (2016) Systemic and topical use of tranexamic acid in spinal surgery: a systematic review. *Glob Spine J* 6:284–295
64. Sukeik M, Alshryda S, Haddad FS, Mason JM (2011) Systematic review and meta-analysis of the use of tranexamic acid in total hip replacement. *J Bone Jt Surg Ser B* 93B:39–46. <https://doi.org/10.1302/0301-620X.93B1.24984>
65. Xing F, Chen W, Long C et al (2020) Postoperative outcomes of tranexamic acid use in geriatric trauma patients treated with proximal femoral intramedullary nails: a systematic review and meta-analysis. *Orthop Traumatol Surg Res* 106:117–126
66. Qi Y, Wang H, Li Y et al (2019) The efficacy and safety of intravenous tranexamic acid in hip fracture surgery: a systematic review and meta-analysis. *J Orthop Transl* 19:1–11
67. Xie J, Hu Q, Huang Q et al (2019) Efficacy and safety of tranexamic acid in geriatric hip fracture with hemiarthroplasty:

- a retrospective cohort study. *BMC Musculoskelet Disord*. <https://doi.org/10.1186/s12891-019-2670-5>
68. Gausden EB, Qudsi R, Boone MD et al (2017) Tranexamic acid in orthopaedic trauma surgery: a meta-analysis. *J Orthop Trauma* 31:513–519. <https://doi.org/10.1097/BOT.0000000000000913>
  69. Piggott RP, Leonard M (2016) Is there a role for antifibrinolytics in pelvic and acetabular fracture surgery? *Ir J Med Sci* 185:29–34
  70. Lack WD, Crist BD, Seymour RB et al (2017) Effect of tranexamic acid on transfusion: a randomized clinical trial in acetabular fracture surgery. *J Orthop Trauma* 31:526–530. <https://doi.org/10.1097/BOT.0000000000000968>
  71. Spittler CA, Row ER, Gardner WE et al (2019) Tranexamic acid use in open reduction and internal fixation of fractures of the pelvis, acetabulum, and proximal femur: a randomized controlled trial. *J Orthop Trauma* 33:371–376
  72. Kashyap S, Mahajan S, Lal M (2019) Effects of topical tranexamic acid during open reduction and internal fixation of acetabular fractures: a retrospective study. *Acta Orthop Traumatol Turc* 53:175–179. <https://doi.org/10.1016/j.aott.2019.03.006>
  73. Jawed A, Ahmed A, Williams MR (2019) Intra-operative cell salvage in pelvic and acetabular fracture surgery: a retrospective comparative study. *Int Orthop* 43:1695–1699. <https://doi.org/10.1007/s00264-018-4104-7>
  74. Bigsby E, Acharya MR, Ward AJ, Chesser TJS (2013) The use of blood cell salvage in acetabular fracture internal fixation surgery. *J Orthop Trauma* 27:e230–e233. <https://doi.org/10.1097/BOT.0b013e3182877684>
  75. Scannell BP, Loeffler BJ, Bosse MJ et al (2009) Efficacy of intraoperative red blood cell salvage and autotransfusion in the treatment of acetabular fractures. *J Orthop Trauma* 23:340–345. <https://doi.org/10.1097/BOT.0b013e31819f691d>
  76. Bridgens JP, Evans CR, Dobson PMS, Hamer AJ (2007) Intra-operative red blood-cell salvage in revision hip surgery: a case-matched study. *J Bone Jt Surg Ser A* 89:270–275. <https://doi.org/10.2106/JBJS.F.00492>
  77. Esper SA, Waters JH (2011) Intra-operative cell salvage: a fresh look at the indications and contraindications. *Blood Transfus* 9:139–147
  78. Odak S, Raza A, Shah N, Clayton A (2013) Clinical efficacy and cost effectiveness of intraoperative cell salvage in pelvic trauma surgery. *Ann R Coll Surg Engl* 95:357–360. <https://doi.org/10.1308/003588413X13629960045715>
  79. Wilson WJ (1989) Intraoperative autologous transfusion in revision total hip arthroplasty—PubMed. *J Bone Jt Surg* 71:8–14
  80. Cheriyan J, Cheriyan T, Dua A et al (2020) Efficacy of intraoperative cell salvage in spine surgery: a meta-analysis. *J Neurosurg Spine* 33:261–269. <https://doi.org/10.3171/2019.12.SPINE19920>
  81. Huët C, Salmi R, Fergusson D et al (1999) A meta-analysis of the effectiveness of cell salvage to minimize perioperative allogeneic blood transfusion in cardiac and orthopedic surgery. *Anesth Analg* 89:861–869. <https://doi.org/10.1097/00000539-199910000-00009>
  82. Firoozabadi R, Swenson A, Kleweno C, Routt MC (2015) Cell saver use in acetabular surgery: does approach matter? *J Orthop Trauma* 29:349–353. <https://doi.org/10.1097/BOT.0000000000000292>
  83. Reddix R, Leng X, Woodall J et al (2010) The effect of incisional negative pressure therapy on wound complications after acetabular fracture surgery—PubMed. *J Surg Orthop Adv* 19:91–97
  84. Deo SD, Tavares SP, Pandey RK et al (2001) Operative management of acetabular fractures in Oxford. *Injury* 32:581–586. [https://doi.org/10.1016/S0020-1383\(00\)00200-X](https://doi.org/10.1016/S0020-1383(00)00200-X)
  85. Kumar A, Shah N, Kershaw S, Clayton A (2005) Operative management of acetabular fractures. A review of 73 fractures—PubMed. *Injury* 36:605–612
  86. Moed BR, Yu PH, Gruson KI (2003) Functional outcomes of acetabular fractures. *J Bone Jt Surg Ser A* 85:1879–1883. <https://doi.org/10.2106/00004623-200310000-00002>
  87. Crist BD, Oladeji LO, Khazzam M et al (2017) Role of acute negative pressure wound therapy over primarily closed surgical incisions in acetabular fracture ORIF: a prospective randomized trial. *Injury* 48:1518–1521. <https://doi.org/10.1016/j.injury.2017.04.055>
  88. Quatman CE, Villarreal ME, Cochran A (2020) Incisional negative pressure wound therapy following surgical repair of lower extremity fractures. *JAMA J Am Med Assoc* 323:513–514
  89. Scalise A, Calamita R, Tartaglione C et al (2016) Improving wound healing and preventing surgical site complications of closed surgical incisions: a possible role of incisional negative pressure wound therapy. A systematic review of the literature. *Int Wound J* 13:1260–1281. <https://doi.org/10.1111/iwj.12492>
  90. Herscovici D, Sanders RW, Scaduto JM et al (2003) Vacuum-assisted wound closure (VAC therapy) for the management of patients with high-energy soft tissue injuries. *J Orthop Trauma* 17:683–688. <https://doi.org/10.1097/00005131-20031000-00004>
  91. Stannard JP, Volgas DA, McGwin G et al (2012) Incisional negative pressure wound therapy after high-risk lower extremity fractures. *J Orthop Trauma* 26:37–42. <https://doi.org/10.1097/BOT.0b013e318216b1e5>
  92. Costa ML, Achten J, Knight R et al (2020) Effect of Incisional negative pressure wound therapy vs standard wound dressing on deep surgical site infection after surgery for lower limb fractures associated with major trauma: the WHIST randomized clinical trial. *JAMA J Am Med Assoc* 323:519–526. <https://doi.org/10.1001/jama.2020.0059>
  93. Stall AC, Becker E, Ludwig SC et al (2009) Reduction of postoperative spinal implant infection using gentamicin microspheres. *Spine (Phila Pa 1976)* 34:479–483. <https://doi.org/10.1097/BRS.0b013e318197e96c>
  94. Hanssen A, Osmon D, Patel R (2005) Local antibiotic delivery systems: where are we and where are we going?—PubMed. *Clin Orthop Relat Res* 437:111–114
  95. Sweet FA, Roh M, Sliva C (2011) Intrawound application of vancomycin for prophylaxis in instrumented thoracolumbar fusions: efficacy, drug levels, and patient outcomes. *Spine (Phila Pa 1976)* 36:2084–2088. <https://doi.org/10.1097/BRS.0b013e3181ff2cb1>
  96. O'Neill KR, Smith JG, Abtahi AM et al (2011) Reduced surgical site infections in patients undergoing posterior spinal stabilization of traumatic injuries using vancomycin powder. *Spine J* 11:641–646. <https://doi.org/10.1016/j.spinee.2011.04.025>
  97. Molinari RW, Khera OA, Molinari WJ (2012) Prophylactic intraoperative powdered vancomycin and postoperative deep spinal wound infection: 1512 consecutive surgical cases over a 6-year period. *Eur Spine J*. <https://doi.org/10.1007/s00586-011-2104-z>
  98. Hill BW, Emohare O, Song B et al (2014) The use of vancomycin powder reduces surgical reoperation in posterior instrumented and noninstrumented spinal surgery. *Acta Neurochir (Wien)* 156:749–754. <https://doi.org/10.1007/s00701-014-2022-z>
  99. Caroom C, Tullar JM, Benton EG et al (2013) Intrawound vancomycin powder reduces surgical site infections in posterior cervical fusion. *Spine (Phila Pa 1976)* 38:1183–1187. <https://doi.org/10.1097/BRS.0b013e31828fcbf5>
  100. Matziolis G, Brodt S, Böhle S et al (2020) Intraarticular vancomycin powder is effective in preventing infections following total hip and knee arthroplasty. *Sci Rep*. <https://doi.org/10.1038/s41598-020-69958-0>
  101. Peng Z, Lin X, Kuang X et al (2021) The application of topical vancomycin powder for the prevention of surgical site infections in primary total hip and knee arthroplasty: a meta-analysis. *Orthop Traumatol Surg Res* 107:102741

102. Qadir R, Costales T, Coale M et al (2021) Vancomycin powder use in fractures at high risk of surgical site infection. *J Orthop Trauma* 35:23–28. <https://doi.org/10.1097/BOT.0000000000001863>
103. Halteh P, Huang J, Wildman HF, Magro CM (2017) Gadolinium-naïve nephrogenic systemic fibrosis of breast mimicking inflammatory breast carcinoma. *Am J Dermatopathol* 39:322–324
104. O'Toole RV, Joshi M, Carlini AR et al (2021) Effect of intrawound vancomycin powder in operatively treated high-risk tibia fractures: a randomized clinical trial. *JAMA Surg*. <https://doi.org/10.1001/jamasurg.2020.7259>
105. Owen MT, Keener EM, Hyde ZB et al (2017) Intraoperative topical antibiotics for infection prophylaxis in pelvic and acetabular surgery. *J Orthop Trauma* 31:589–594. <https://doi.org/10.1097/BOT.0000000000000941>
106. Cichos KH, Spittler CA, Quade JH et al (2021) Intrawound antibiotic powder in acetabular fracture open reduction internal fixation does not reduce surgical site infections. *J Orthop Trauma* 35:198–204. <https://doi.org/10.1097/BOT.0000000000001943>
107. Childs HA, Cole T, Falkenberg E et al (2000) A prospective evaluation of the timing of postoperative radiotherapy for preventing heterotopic ossification following traumatic acetabular fractures. *Int J Radiat Oncol* 47:1347–1352. [https://doi.org/10.1016/S0360-3016\(00\)00582-4](https://doi.org/10.1016/S0360-3016(00)00582-4)
108. Burnet NG, Nasr P, Yip G et al (2014) Prophylactic radiotherapy against heterotopic ossification following internal fixation of acetabular fractures: a comparative estimate of risk. *Br J Radiol*. <https://doi.org/10.1259/bjr.20140398>
109. Kaempffe FA, Bone LB, Border JR (1991) Open reduction and internal fixation of acetabular: fracture. *J Orthop Trauma* 5:439–445
110. Nauth A, Giles E, Potter BK et al (2012) Heterotopic ossification in orthopaedic trauma. *J Orthop Trauma* 26:684–688. <https://doi.org/10.1097/BOT.0B013E3182724624>
111. Firoozabadi R, O'Mara TJ, Swenson A et al (2014) Risk factors for the development of heterotopic ossification after acetabular fracture fixation. *Clin Orthop Relat Res* 472:3383–3388. <https://doi.org/10.1007/S11999-014-3719-2>
112. Elhassan Y, Abdelhaq A, Piggott RP et al (2016) Heterotopic Ossification following acetabular fixation: incidence and risk factors: 10-year experience of a tertiary centre. *Injury* 47:1332–1336. <https://doi.org/10.1016/J.INJURY.2016.03.002>
113. Brooker A, Bowerman J, Robinson R, Riley L (1973) Ectopic ossification following total hip replacement. Incidence and a method of classification—PubMed. *J Bone Jt Surg* 55:1629–1632
114. Thomas B (1992) Heterotopic bone formation after total hip arthroplasty—PubMed. *Orthop Clin N Am* 23:347–358
115. Slone HS, Walton ZJ, Daly CA et al (2015) The impact of race on the development of severe heterotopic ossification following acetabular fracture surgery. *Injury* 46:1069–1073. <https://doi.org/10.1016/J.INJURY.2015.01.039>
116. Baschera D, Rad H, Collopy D, Zellweger R (2015) Incidence and clinical relevance of heterotopic ossification after internal fixation of acetabular fractures: retrospective cohort and case control study. *J Orthop Surg Res* 10:1–7. <https://doi.org/10.1186/S13018-015-0202-Z>
117. Moore KD, Goss K, Anglen JO (1998) Indomethacin versus radiation therapy for prophylaxis against heterotopic ossification in acetabular fractures. *J Bone Jt Surg*. 80-B:259–263. <https://doi.org/10.1302/0301-620X80B20800259>
118. Sagi HC, Jordan CJ, Barei DP et al (2014) Indomethacin prophylaxis for heterotopic ossification after acetabular fracture surgery increases the risk for nonunion of the posterior wall. *J Orthop Trauma* 28:377–383. <https://doi.org/10.1097/BOT.0000000000000049>
119. Matta JM, Siebenrock KA (1997) Does indomethacin reduce heterotopic bone formation after operations for acetabular fractures? *J Bone Jt Surg* 79:959–963. <https://doi.org/10.1302/0301-620X79B60790959>
120. Griffin SM, Sims SH, Karunakar MA et al (2013) Heterotopic ossification rates after acetabular fracture surgery are unchanged without indomethacin prophylaxis. *Clin Orthop Relat Res* 471:2776–2782. <https://doi.org/10.1007/S11999-013-2871-4>
121. Cheng L, Long H-T, Sun B-H et al (2017) The efficacy of a multimodal analgesia protocol in preventing heterotopic ossification after acetabular fractures surgery. *Int J Clin Pharm* 39(4):826–830. <https://doi.org/10.1007/S11096-017-0476-9>
122. Mourad WF, Packianathan S, Shourbaji RA et al (2012) A prolonged time interval between trauma and prophylactic radiation therapy significantly increases the risk of heterotopic ossification. *Int J Radiat Oncol* 82:e339–e344. <https://doi.org/10.1016/J.IJROBP.2011.06.1981>
123. Haas ML, Kennedy AS, Copeland CC et al (1999) Utility of radiation in the prevention of heterotopic ossification following repair of traumatic acetabular fracture. *Int J Radiat Oncol* 45:461–466. [https://doi.org/10.1016/S0360-3016\(99\)00191-1](https://doi.org/10.1016/S0360-3016(99)00191-1)
124. Slawson RG, Poka A, Bathon H et al (1989) The role of postoperative radiation in the prevention of heterotopic ossification in patients with post-traumatic acetabular fracture. *Int J Radiat Oncol* 17:669–672. [https://doi.org/10.1016/0360-3016\(89\)90122-3](https://doi.org/10.1016/0360-3016(89)90122-3)
125. Davis JA, Roper B, Munz JW et al (2016) Does postoperative radiation decrease heterotopic ossification after the Kocher–Langenbeck approach for acetabular fracture? *Clin Orthop Relat Res* 474:1430–1435. <https://doi.org/10.1007/S11999-015-4609-Y>
126. Georhakopoulos I, Kouloulis V, Kougiountzopoulou A et al (2020) Radiation therapy for the prevention of heterotopic ossification: efficacy and toxicity of single fraction radiotherapy. *Orthop Rev (Pavia)* 12:90–94. <https://doi.org/10.4081/OR.2020.8577>

**Publisher's Note** Springer Nature remains neutral with regard to jurisdictional claims in published maps and institutional affiliations.